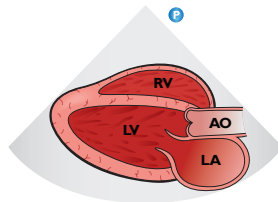
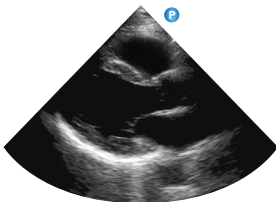
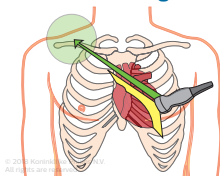
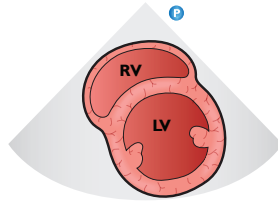
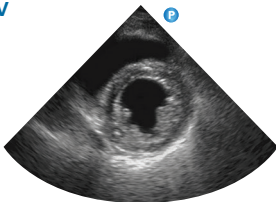
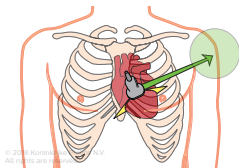


Introduction to transthoracic echo – POC views

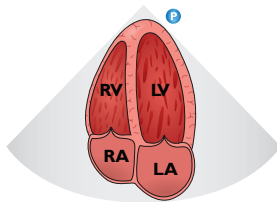
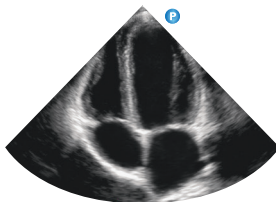
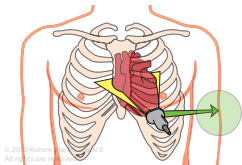
Parasternal long-axis



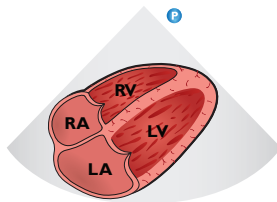
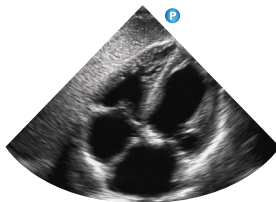
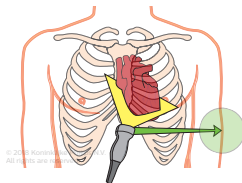
Parasternal short-axis LV



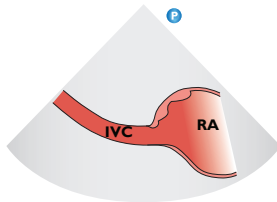
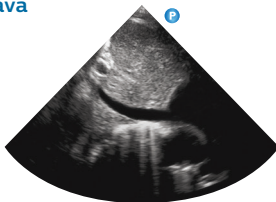
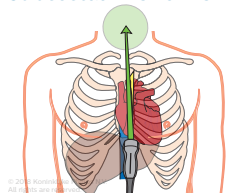
Apical four-chamber



Subcostal four-chamber



Subcostal inferior vena cava



To view the complete
"Introduction to
transthoracic echo"
tutorial visit:

[www.philips.com/
CCEducation](http://www.philips.com/CCEducation)



©2018 Koninklijke Philips N.V.
All rights are reserved.

Philips reserves the right to make
changes in specifications and/or
to discontinue any product at any
time without notice or obligation
and will not be liable for any
consequences resulting from the
use of this publication.

ULT-18-38110 * JAN 2018