



PHILIPS

Computed tomography

Case studies

Utility of IQon Spectral CT in **cardiac imaging**

Cardiac imaging is a challenging procedure where it is necessary to image a motion-free heart. This requires a scanner that has the speed to capture the cardiac anatomy.



CT has become the standard clinical test for a variety of cardiovascular conditions. Within cardiac imaging, clinicians are interested in the assessment of coronary artery disease (CAD) and its impact on function. In addition, cardiac CT is also used for the assessment of coronary stents for in-stent re-stenosis, and for planning of complex cardiac interventional procedures such as transcatheter aortic valve implantation (TAVI).

With spectral capabilities, along with a fast rotation speed (0.27 sec, standard temporal resolution of 135 ms in Step & Shoot Cardiac with added improvements via adaptive multi-cycle reconstruction in helical), the IQon Spectral CT is ideally suited to address cardiac imaging challenges. Spectral reconstructions, which include (but are not limited to) mono-energetic (MonoE) and Iodine no Water, are always available either prospectively or retrospectively along with the standard conventional reconstructions.

In contrast to conventional reconstructions, which represent polychromatic X-ray, MonoE reconstructions (also Hounsfield Unit [HU]-based) show attenuation as if a single monochromatic energy (keV) was used to scan. These reconstructions can be displayed in

real time, representing 161 different single energy levels between 40 and 200 keV. These MonoE reconstructions have multiple applications such as boosting of iodine signal (lower MonoE), improvement of contrast-to-noise ratio (CNR) (again lower MonoE), and reduction in calcium blooming, beam hardening and metal artifact (higher MonoE).

Every pixel displayed in reconstruction represents components that behave like iodine and water. Unlike MonoE, which is a HU-based image, Iodine no Water is a material density image that represents the iodine component with the water component suppressed. The iodine content is shown within a Region of Interest and reported in mg/ml. In general, while Iodine no Water is typically used to show iodine uptake, it has also been shown to enable assessment of the coronary arteries in the vicinity of calcium, while at the same time maintaining the contrast enhancement in the lumen.

The following is a collection of case studies obtained from various clinical sites from around the world, demonstrating the cardiac imaging capabilities of the IQon Spectral CT.

Case study 1

Clinique de Genolier
Geneva, Switzerland

This case study demonstrates the IQon Spectral CT's capability of performing low-dose cardiac examinations, using the helical scan mode. A symptomatic but low-risk male patient with atypical chest pain was scanned on the IQon Spectral CT for a quick exclusion of coronary artery disease (CAD). A retrospectively gated helical coronary CTA was performed, with ECG-controlled tube modulation to optimize radiation dose. The scan was completed without any complication at a radiation dose of 1.5 mSv. The conventional images reconstructed with iterative model reconstruction (IMR) were loaded into the Comprehensive Cardiac Application (CCA). Curved multi-planar reformation (CMPR) images were generated to evaluate the coronary arteries. All coronary artery segments were assessed. No disease was found. Figure 1a is a volume-rendered representation of the left coronary artery tree, and Figure 1b shows the CMPR of the left anterior descending artery (LAD).

Since there was no pathology and the coronaries were well visualized with contrast, the conventional reconstructions were sufficient to make a diagnosis. However, spectral data is always available for further examination if needed.

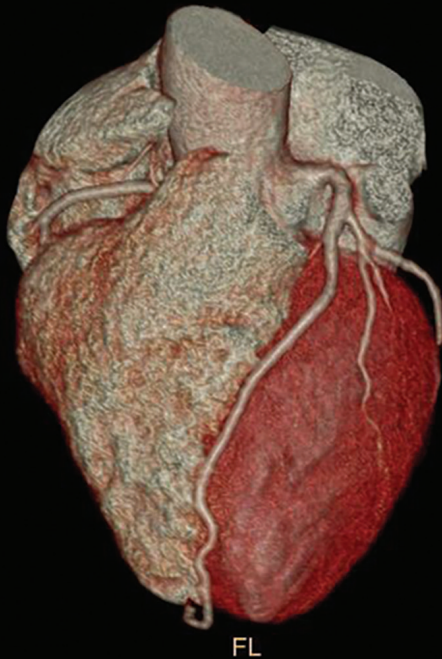

Figure 1a: Volume rendered image showing the left coronary artery system

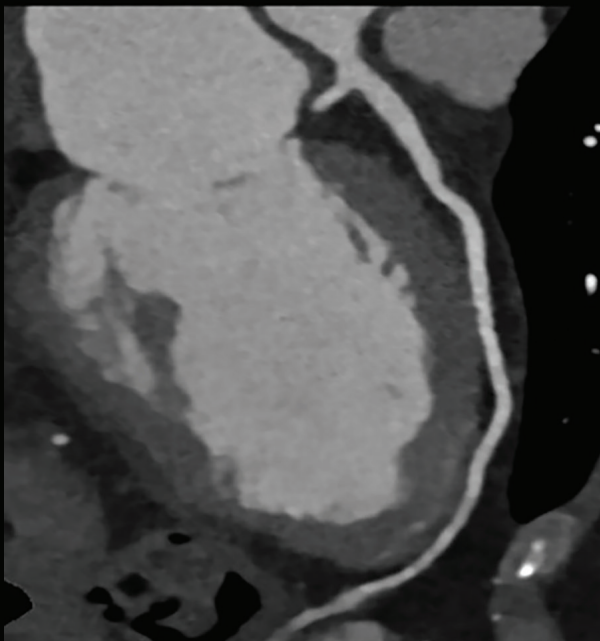


Figure 1b: Curved MPR of the LAD

Case study 2

Kumamoto Chuo Hospital
Kumamoto, Japan

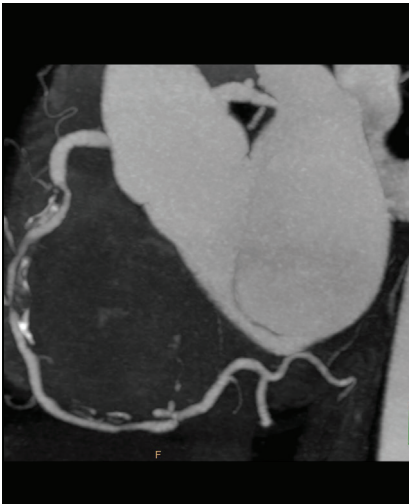

Figure 2a: RCA, Conventional

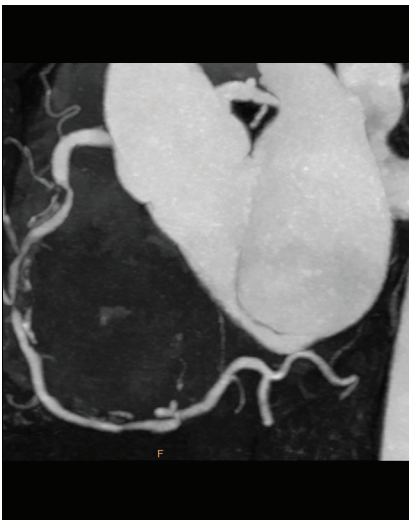


Figure 2b: RCA Iodine no Water

Patient was admitted to the emergency department and referred to CT for an evaluation of chest pain. The patient was scanned on the IQon Spectral CT. The spectral based images were loaded into the Comprehensive Cardiac Application (CCA). Curved multi-planar reformation (CMPR) images were generated to evaluate the multiple vessel disease. All coronary artery segments were assessed. Spectral results such as Iodine no Water and MonoE reconstructions were evaluated on Philips Spectral Magic Glass and used for the assessment of complex plaques.

The severe non-calcified plaque in the mid portion of the right coronary artery (RCA, segment 2) was better visualized using Iodine no Water compared to conventional images (Figure 2a, 2b). Additionally, a complex mixed plaque was seen in the mid portion of the left anterior descending artery (LAD, segment 7). Figure 2c is a volume-rendered (VR) representation of the left arterial tree. The CMPRs of the LAD are shown in Figure 2d (conventional reconstructions) and Figure 2e (MonoE reconstructions at 90 keV), with MonoE reconstructions demonstrating reduced calcium blooming compared to the conventional reconstructions.

Based on the CT findings, this patient was then sent for an invasive cardiac angiography (ICA) and diagnosed with a severe flow-limiting 90% stenosis in the mid-segment of the RCA (segment 2) and in mid-LAD (segment 7).

Figure 2c: LAD, volume rendering

Figure 2d: LAD, conventional

Figure 2e: LAD, MonoE 90 keV

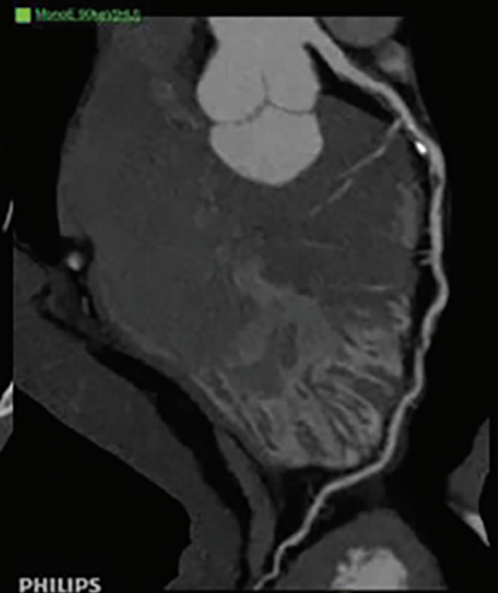
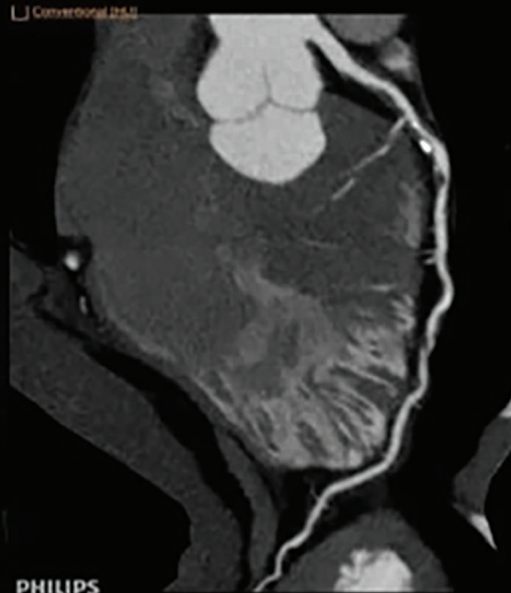
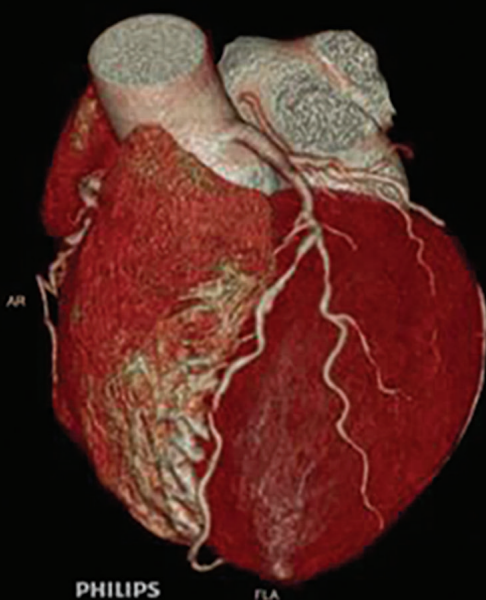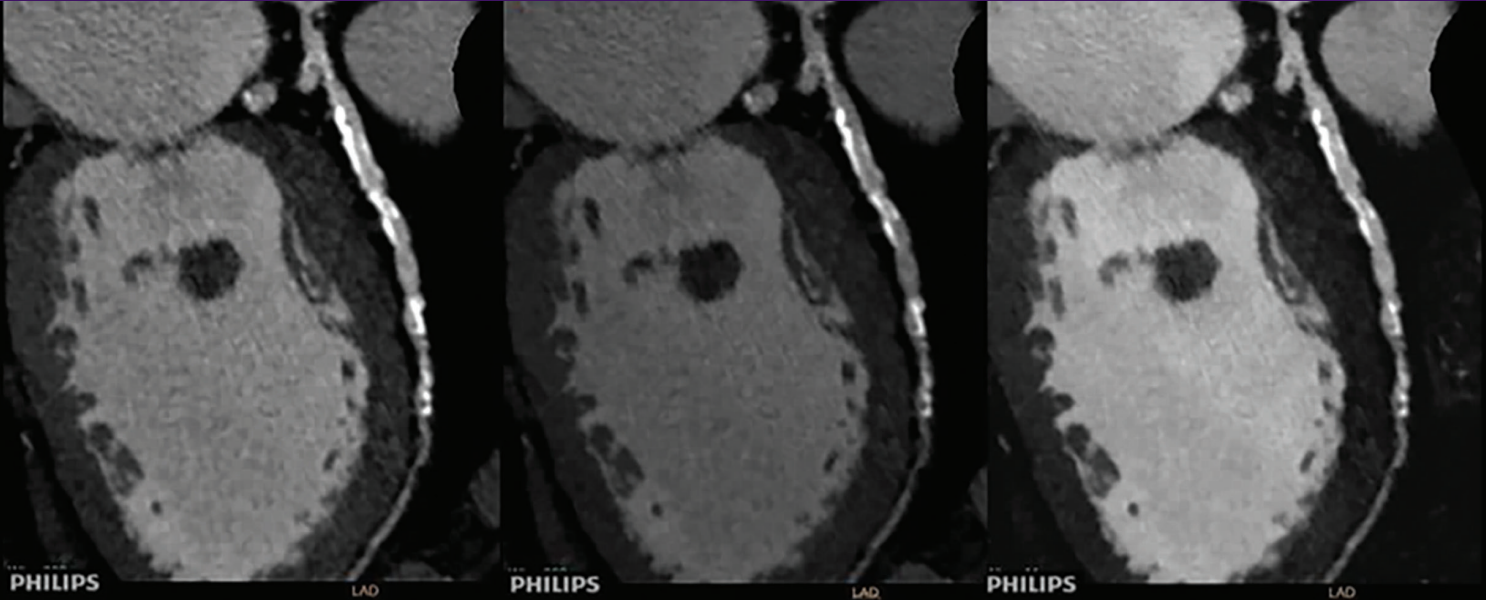


Figure 3a: Conventional

Figure 3b: MonoE 90 keV

Figure 3c: Iodine no Water

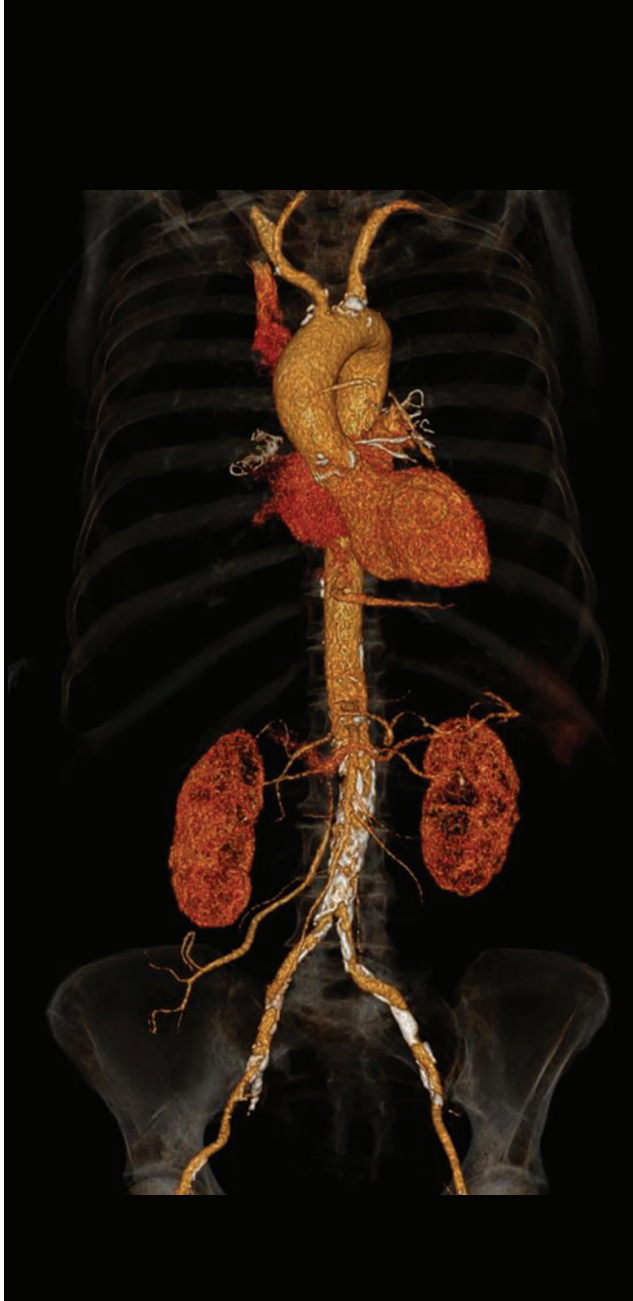

Case study 3

University Medical Center
Utrecht, The Netherlands

Patient was referred to CT for the assessment of atypical chest pain, and was scanned on the IQon Spectral CT. A low-dose Step & Shoot Cardiac was performed. All coronary segments were assessed. The patient was found to have multi-vessel disease in both RCA and LAD in addition to the focal non-calcified lesion at the left main ostium. The CMPRs (Figures 3a-c) showed extensive calcifications in the mid and distal LAD.

Spectral results such as MonoE (90 keV) (Figure 3b) and Iodine no Water (Figure 3c) enabled improved assessment of the diseased area via a reduction in the calcium blooming compared to the conventional reconstructions (Figure 3a).



Thoracic abdominal CTA

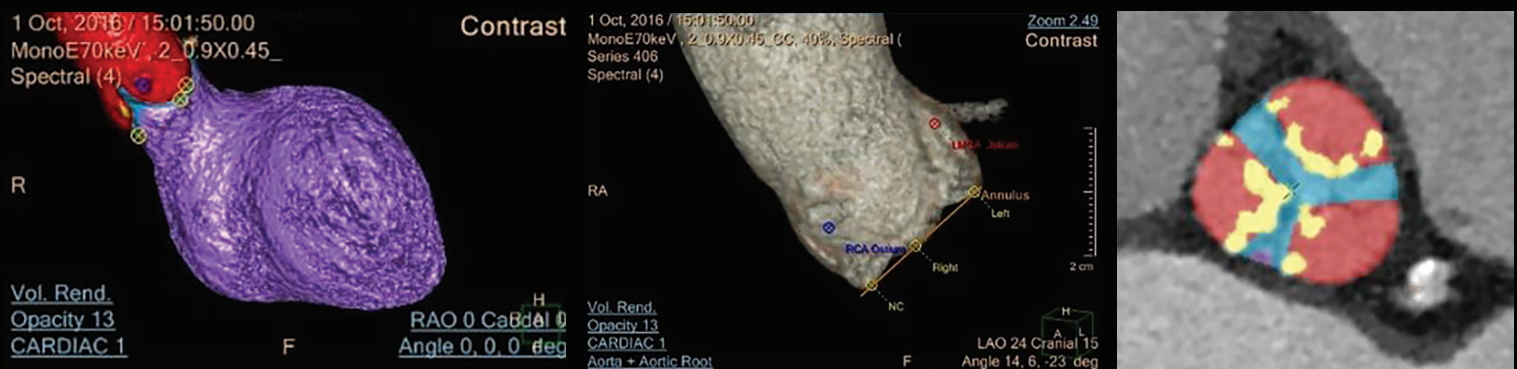
Case study 4

Pre-transcatheter aortic valve implantation (TAVI) CTA
Claraspital
Basel, Switzerland

Patient was referred for a pre-TAVI evaluation on the IQon Spectral CT. First, a contrast-enhanced ECG-gated scan was performed on the cardiac anatomy for the imaging of the aortic root, and was immediately followed by a non-gated chest-abdomen-pelvis CTA with a minimal delay. A total contrast of 80 ml was given to the patient for both acquisitions. The gated scan showed aortic valve insufficiency via the motion of valve leaflets (an indication of aortic stenosis), and also provided critical measurements for pre-planning, such as annulus dimensions, distance of the coronary ostia to the annulus plane, and optimal deployment angle to be used during the invasive procedure. The non-gated CTA helped with the assessment of the access route for dimensions and tortuosity severity.

This demonstrated the capability of the IQon Spectral CT for pre-planning of the interventional procedure with low contrast volumes for advanced CT applications. In addition, a recent work has shown further reduction in contrast volume in these examinations [1].

TAVI planning application found on the IntelliSpace Portal



[1] Reducing iodinated contrast agent concentrations with dual energy CT: a multivendor dynamic phantom study van Hamersvelt RW , Eijssvoegel NG, Muhl C, de Jong PA, Bults N , Das M, Wildberger JE, Leiner T, Willemsink MJ; European Congress of Radiology (ECR), Vienna, 2017

Case study 5

Minamino Heart Clinic
Tokyo, Japan

A 59-year old male who had undergone a percutaneous coronary intervention (PCI) in 2013 presented with recurring chest pain that radiated up into his neck and into his back. A retrospectively gated cardiac CT was performed on the IQon Spectral CT to investigate the cause of this recent discomfort. The reconstruction kernel was CB, and its noise reduction level called spectral level was 0. The resulting spectral-based images were loaded into the Comprehensive Cardiac Application (CCA). All coronary artery segments were assessed. Curved multi-planar reformation (CMPR) images were generated to evaluate the coronary stent in the proximal LAD. Spectral results using Spectral Magic Glass, such as Iodine no Water and MonoE reconstructions, were used for further examination.

For this patient, stent assessment was not possible using conventional reconstructions (Figure 5a). However, the Iodine no Water reconstruction (Figure 5b) provided the optimum visualization of the stent, demonstrating a clear re-stenosis in the proximal portion. In addition, the Z Effective image (Figure 5c) showed the corresponding color representation.* The findings were confirmed on the invasive coronary angiography (ICA) (Figure 5d). The spectral results provided the clinician the confidence needed to send the patient to the cath lab for further evaluation.

* Results from case studies are not predictive of results in other cases; results in other cases may vary.

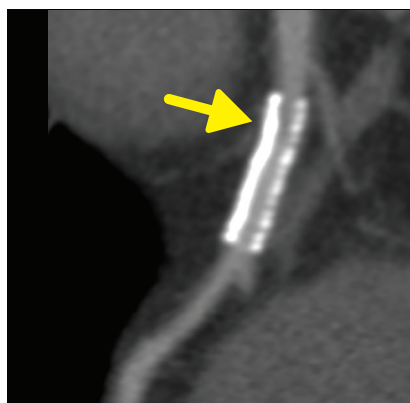


Figure 5a

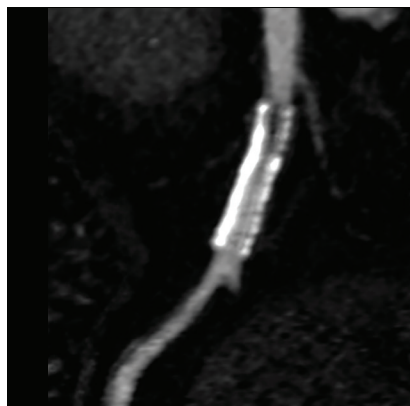

Figure 5b

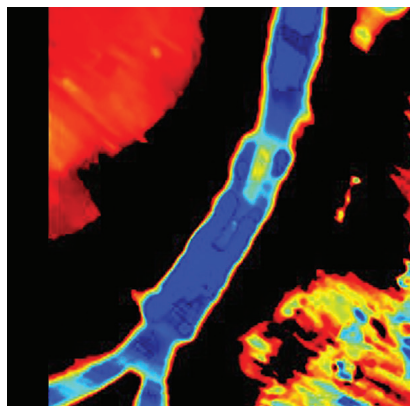


Figure 5c

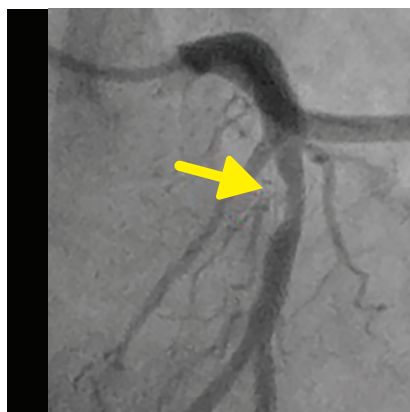

Figure 5d

Case study 6

University Hospitals
Cleveland, Ohio, USA

A middle-aged male with atrial fibrillation was scanned on the IQon Spectral CT for the assessment of the left atrial and the pulmonary vein anatomy. The conventional reconstruction of the arterial phase showed an area of low attenuation in the left atrial appendage, typically associated with either a clot or an area with slow flow (Figure 6a). A delayed scan was performed for confirmation.

The conventional reconstruction from this delayed scan appeared to show filling of the atrial appendage, but could not be confirmed by the clinician because of the lack of contrast enhancement (Figure 6b). In contrast, the 50 keV MonoE reconstruction allowed the clinician to confirm that the left atrial appendage was filled with contrast, affirming it to be slow flow and not a clot (Figure 6c).

Figure 6a: Arterial phase (Conventional)

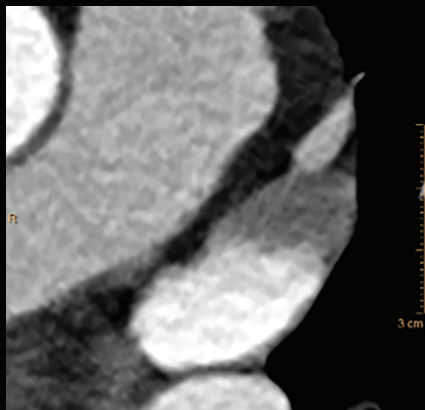


Figure 6b: Delayed phase (Conventional)

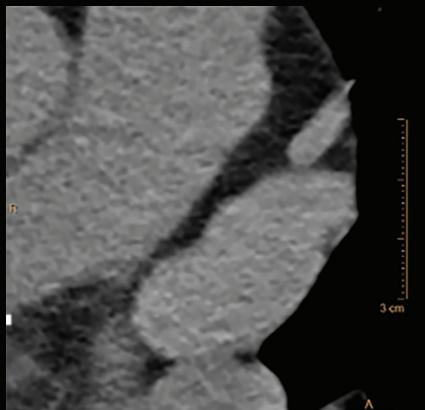
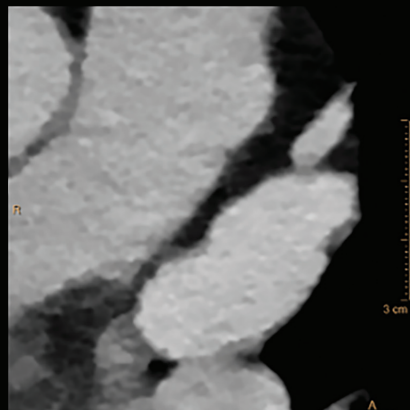


Figure 6c: Delayed phase (50 keV MonoE)



Conclusion

Spectral results from the IQon Spectral CT offer the opportunity to gain additional clinical insights for assessment of cardiac diseases. Spectral reconstructions such as Iodine no Water and MonoE result in improved visualization of complex coronary plaques by reducing calcium blooming compared to conventional reconstructions. The case examples

shown here demonstrate the benefits of the IQon Spectral CT – with spectral information always available prospectively and retrospectively.

Clinical relevance

Philips IQon Spectral CT improves diagnostic confidence by enabling assessment of various cardiac diseases and their impact on function.