

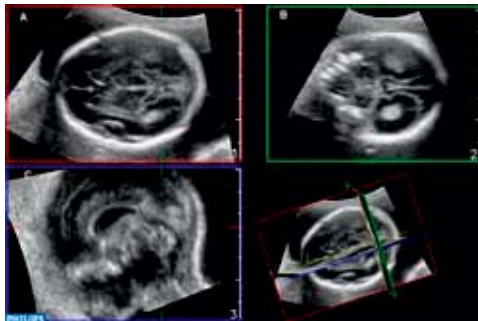
# An introduction to fetal neurosonography using three-dimensional ultrasound

Taddei F, Fratelli N, Prefumo F, Franceschetti L, Signorelli M and Frusca T  
Maternal Fetal Medicine Unit, Department of Obstetrics and Gynaecology  
University of Brescia, Italy

Transabdominal 2D ultrasound based on axial planes has, so far, been the standard approach for the imaging of fetal central nervous system abnormalities. In recent years three-dimensional ultrasound has shown to be a potentially useful tool both in basic and detailed examination of the fetal brain. The aim of this paper is to describe the possible applications of this technique.

## Multiplanar mode: nomenclature

The multiplanar mode is probably the most useful tool for assessment of the fetal central nervous system (CNS). With this mode of display, the plane parallel to the acquisition plane or “start” appears in the upper left corner of the screen and is identified with the letter A. The plane perpendicular to A, but parallel to the ultrasound beam, is identified with the letter B and appears in the upper right corner. The plane that is both perpendicular to the “start” scan and the ultrasound beam is defined as C (Figure1).



**Figure 1.** Displays the spatial orientation of planes (1), (2), and (3). A is the plane parallel to the acquisition or “start” scan. B and C are the reconstructed orthogonal planes. The fourth view shown is the MPR.

### Physical principles

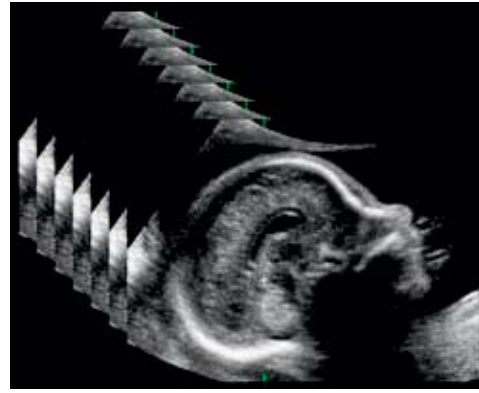
Volumes acquired by 3D ultrasound are normally acquired by a transducer that sweeps the ultrasound beam mechanically across the volume of interest (Figure 2). Volume acquisition is subject to the same physical limits as a 2D scan, and the quality of the images mainly depends on the number of sections obtained during the acquisition. In order to get images of good quality it is also important to optimize the quality of the image in the acquisition plane, and to set the angle of acquisition of the transducer sweep according to the gestational age of the fetus and the approach (axial, coronal or sagittal) chosen to acquire the volume. The higher the quality of the volume and the acquisition angle, the longer the acquisition time. When the fetal brain is scanned with 2D ultrasound using sagittal and coronal planes, the resolution of anatomic detail is usually very high. Visualization is not improved by adding 3D examination. The advantage of 3D ultrasound imaging is the speed at which a volume is obtained, allowing off-line analysis that is not influenced by fetal movements, the precise identification of structures obtained comparing the three orthogonal planes, and the storage and exchange of data.

### Imaging

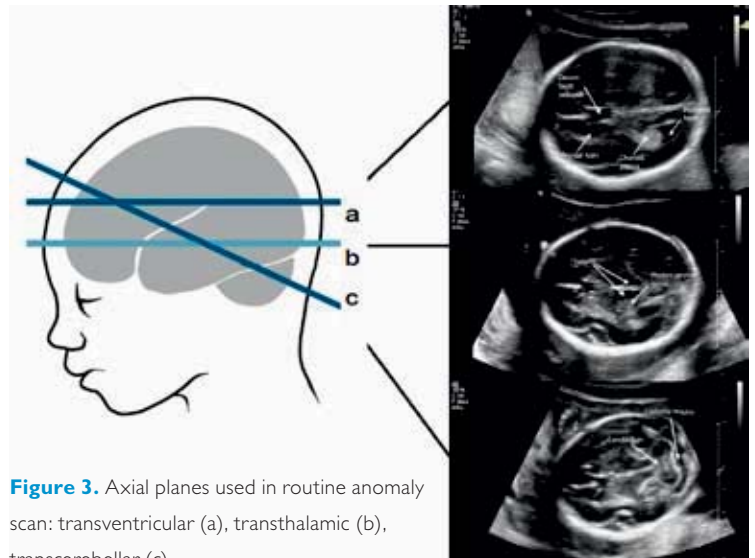
At mid gestation, a basic imaging for the most common malformations of the fetal brain can be done using three standard axial planes, as defined by the ISUOG (International Society of Ultrasound in Obstetrics and Gynecology). The transventricular and transcerebellar planes (Figure 3) allow visualization of all the cerebral structures relevant to assess the anatomic integrity of the brain, while the transthalamic plane can be added mainly for biometric measurements. Starting from a volume acquired with three-dimensional ultrasound (using a mechanical angle ranging from about 45 degrees at mid gestation to 65-70 degrees in the third trimester) the clinician can analyze the volume off-line, and through navigation in the volume can identify the three different standard planes.

### Detailed fetal neurosonography

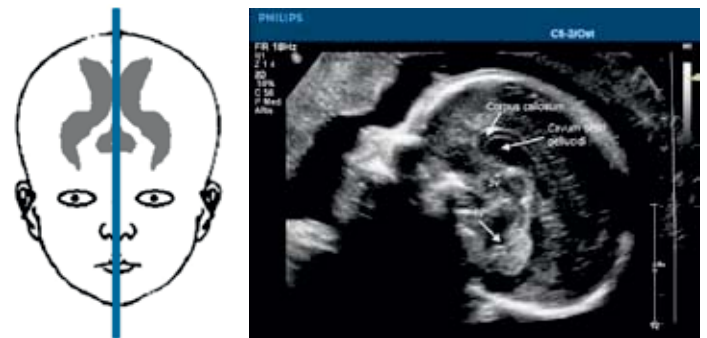
Detailed fetal neurosonography is based on a multiplanar approach obtained through the analysis of a series of axial, sagittal and coronal views standardized by Timor-Tritsch. Traditionally, sagittal and coronal views are acquired transvaginally, and can be acquired transabdominally only if the fetus is in the breech presentation. Even then, this can be difficult, as the scanning has to be done through fontanelles and sutures, which may involve manipulating the fetus. The midsagittal view is probably the most useful complement to the three standard axial views allowing detailed investigation of the corpus callosum and the posterior fossa (Figure 4). The main advantage of three-dimensional ultrasound is that it allows easy



**Figure 2.** Volumes acquired by 3D ultrasound contain a series of 2D planes



**Figure 3.** Axial planes used in routine anomaly scan: transventricular (a), transthalamic (b), transcerebellar (c).



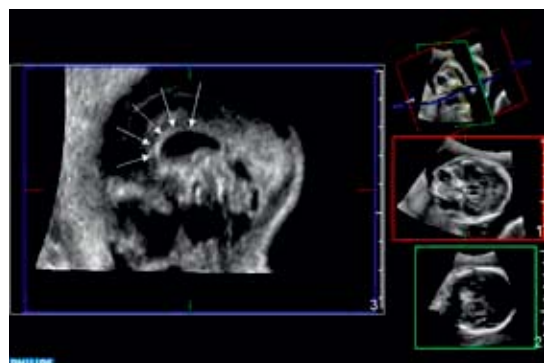
**Figure 4.** Midsagittal view of the fetal brain.

visualization of the midline structures that can be difficult to see with the traditional 2D transabdominal approach. When the volume is acquired transabdominally with a single sweep starting from the transcerebellar plane, it is possible to quickly obtain information on the corpus callosum, the cerebellar vermis and the other midline structures.

In order to reduce the shadowing of the skull base on the cerebellum and the brain stem, it is useful to keep an angle of about 45° between the midline structures and the ultrasound beam during acquisition. Compared with obtaining specific views transabdominally or transvaginally, which can be very difficult and time consuming, this is easier and faster for the sonographer and more comfortable for the patient. Once the volume has been acquired, examining the brain is also fast. Access to all the standard axial, sagittal and coronal views is easy, using multiplanar views and customized oblique views.

### Corpus callosum

Because of its “comma-like” shape the corpus callosum cannot be visualized in axial planes. As coronal planes allow the visualization of only a small portion at a time, the sagittal view is considered to be the gold standard. Using 2D ultrasound the corpus callosum appears as an anechoic or hypoechoic structure; hyperechogenicity is strongly suspicious of abnormality, mainly callosal lipomas. With an acceptable quality of 3D cerebral multiplanar images the corpus callosum can be visualized in the sagittal plane. An important learning point is that in 3D reconstructed sagittal images, the corpus callosum, which is hypoechoic, cannot be clearly differentiated from the cavum septi pellucidi, while an hyperechoic comma shaped structure is often noted above the cavum. Given that callosal lipomas are extremely rare, it is likely that hyperechogenicity is caused by the simultaneous use of 3D pixel reconstruction and XRES processing. This hyperechoic structure is an artifact and represents the interface between the cingulate gyrus, the cingulate sulcus, cerebrospinal fluid and the blood flow in the callosal arteries (Figure 5).

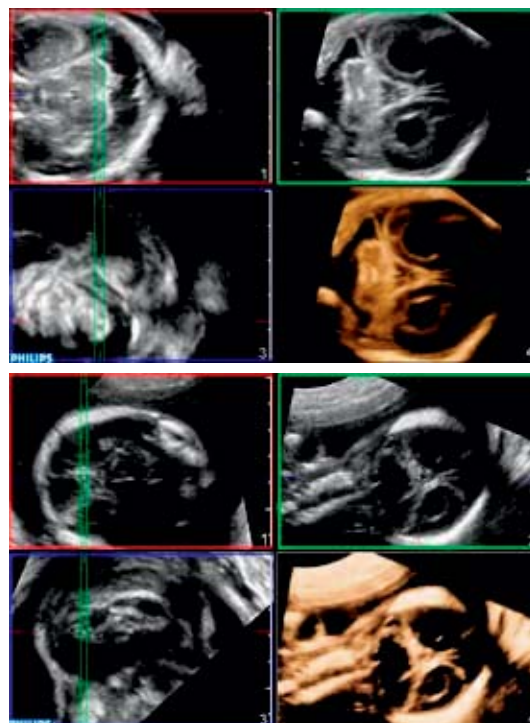


**Figure 5.** The image illustrates a 3D reconstructed midsagittal view of the fetal brain. Arrows point to the hyperechoic “comma-like” artifact overlying the cavum septi pellucidi.

Between 20 and 24 weeks of gestation, the possibility to visualize the corpus callosum from reconstructed 3D volumes is entirely dependent on the position of the fetal head. The appearance of the corpus callosum in the reconstructed image is also dependent on the plane of volume acquisition. Thus, in the mid-sagittal planes the corpus callosum is seen as a thin sonolucent strip with well defined echogenic contours; whereas in the reconstructed midsagittal sections from axial acquisition planes the corpus callosum is not seen, but there is a comma-shaped echogenic structure overlying the cavum septi pellucidi instead.

### Posterior fossa abnormalities

A recent study showed that the key anatomical features of Dandy–Walker complex and megacisterna magna can be visualized and quantified prenatally by ultrasound. Dandy–Walker malformation is characterized by upward displacement of the tentorium and by absent or significantly hypoplastic vermis. Dandy–Walker variant is characterized by a less severe hypoplasia of the vermis and by an upward rotation of the vermis, but there is no upward displacement of the tentorium. Megacisterna magna is characterized by an enlarged cisterna magna (above 10 mm) with an otherwise normal brain anatomy. Advantages provided by three-dimensional ultrasound in this field are the possibility of off-line navigation of the volume, and the possibility of selecting different rendering filters in order to improve the visibility of the various anatomical landmarks, such as the tentorium cerebelli.



**Figure 6.** Multiplanar visualization comparing a normal posterior fossa (a) and a Dandy–Walker malformation (b) characterized by severe hypoplasia of the cerebellar vermis and upward displacement of the tentorium

### Fetal spine

The most frequent severe spinal abnormality, open spina bifida, is usually associated with abnormal intracranial anatomy at mid gestation. Three-dimensional ultrasound with the multiplanar mode can help in the definition of the level of the spinal defect. During routine anomaly scan, however, a longitudinal section of the fetal spine should always be obtained to look for other spinal malformations including vertebral abnormalities and sacral agenesis. This can be done more easily using 3D ultrasound. Using as an acquisition scanning plane of the longitudinal view of the spine, and aligning the transducer with the midsagittal plane of the fetus from the back, it is possible, using the skeletal rendering mode, to demonstrate the three ossification centers of each vertebra.

### Different approaches to volume acquisition: transfrontal, sagittal or coronal

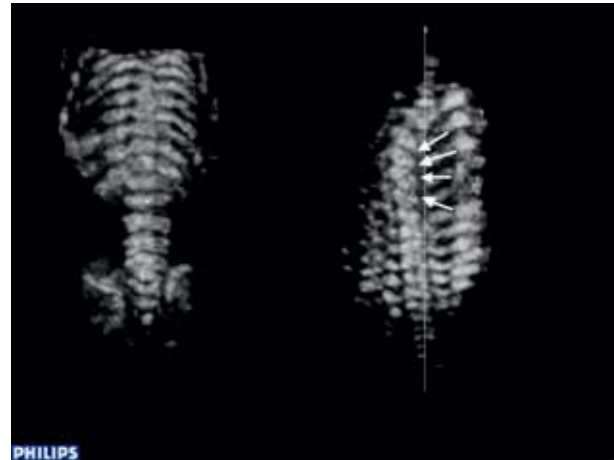
In the sagittal approach the acquisition plane is aligned with the sagittal suture, while in the coronal mode the probe is aligned with the coronal suture. A wide angle of rotation (60–80 degrees) is usually necessary to include the entire fetal brain. Visualization of the fetal brain with this approach is better, but more difficult to obtain than that achieved with the standard axial technique. The acoustic window of bregmatic fontanelle allows a better visualization of the frontal and parietal area. Posteriorly, the low thickness of the sagittal suture results in bilateral shadows. When analyzing a 3D volume with this approach, clear visualization of both occipital lobes is usually impossible (Figure 8). While performing a 2D ultrasound examination in real time, this problem can be overcome by tilting the transducer to visualize the two sides at different times. A good visualization of these structures can be achieved if the posterior fontanelle is used as an acoustic window.

In the transfrontal approach, the ultrasound beam is aligned with the frontal suture and a midsagittal view of the fetal facial profile is obtained in order to use the metopic suture as an acoustic window. Using a mechanical angle of 30 degrees, it is possible to visualize all the midline structures with a better spatial resolution than with 3D axial approach.

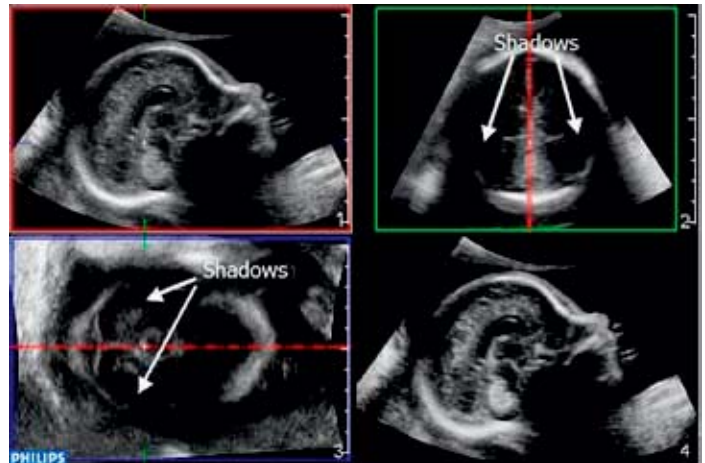
### Different tools to visualize the fetal central nervous system

#### Multiplanar view

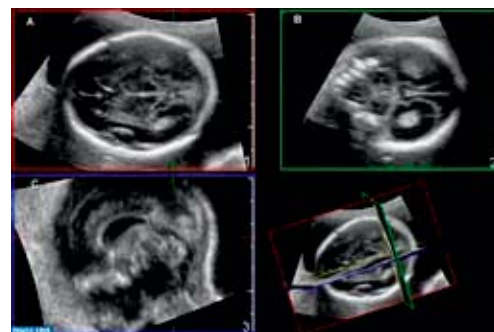
The multiplanar view (Figure 9) allows the operator to identify structures by comparing the three orthogonal planes, to rotate the images in order to view them in the correct anatomical position, and to navigate in different planes simultaneously.



**Figure 7.** Three-dimensional ultrasound images of the fetal spine obtained using a sagittal view as a start scan. The figure compares a normal spine (a) and a spine with thoracic lateral hemivertebrae (b).



**Figure 8.** The figure shows acoustic shadowing covering the occipital lobes when a 3D volume is acquired with a transfrontal approach.



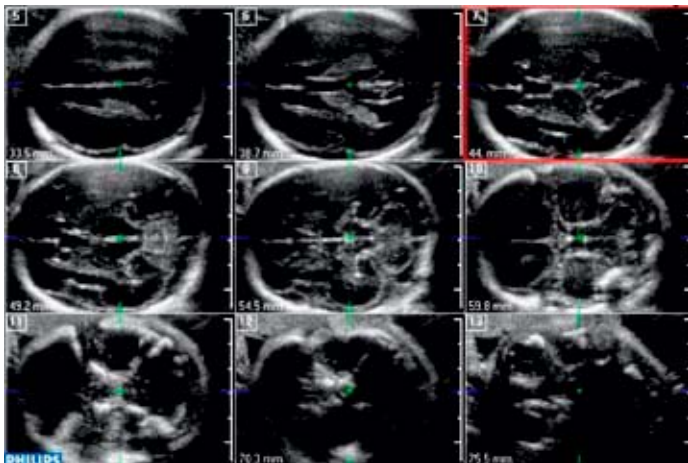
**Figure 9.** Multiplanar views allow simultaneous navigation in all three planes: A, B and C.

## iSlice

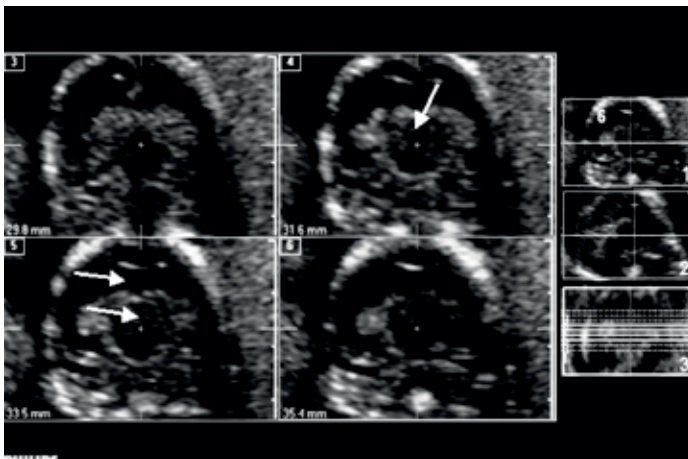
iSlice presents the volume of interest in a series of slices, similar to those from CT or MR (Figure 10). The obstetrician can define the number and the distance between the slices.

## Rendering and thick slice rendering

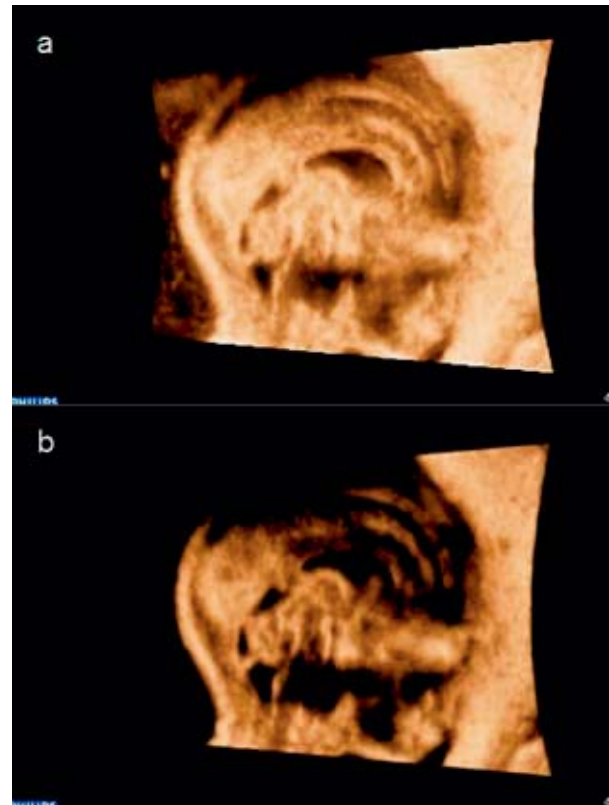
The various parameters for rendering make the perception of different kinds of tissues and fluid filled spaces better. This includes improving contrast resolution, for example, to examine the cerebellar tentorium, changing the threshold to remove artifacts and noise, or using transparency to reveal surfaces. For spinal examinations though, the skeletal rendering soft tissue can be separated out, to show just the bony component with vertebral ossification centers. A better impression of the extent of a structure and a better contrast resolution can sometimes be obtained with thick slice rendering.



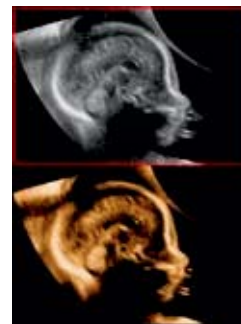
**Figure 10.** Volume of a normal fetal head acquired with an axial approach is visualized using the iSlice display.



**Figure 11.** A case of holoprosencephaly in a fetus at 15 weeks of gestation showed using iSlice.



**Figure 12.** The images show the same image visualized using different rendering settings.



**Figure 13.** The images show the effect of thick slice rendering (b) on a midsagittal view of the fetal head. The superimposition of different layers of tissue improves the visualization.

## Conclusion

The main advantage of three-dimensional ultrasound of the fetal central nervous system is the possibility of obtaining an infinite number of different scanning planes starting from a single volume acquisition. Reconstructed planes are useful for the rapid assessment of normal anatomy in standard examinations, and for evaluation of abnormal cases particularly when a direct 2D scan cannot be obtained because of fetal position. A further potential advantage of 3D ultrasound, is that acquired volumes can be easily sent for consultation to centers that have specialist expertise in fetal neurosonology. Because the information is complete, the teleconsultants have uncompromised availability of the views that they prefer to use, without the imaging center having to acquire an extended number of predefined cross-sections. Similarly, access to the full volume is valuable in teaching, because it allows demonstration of the spatial relationship between anatomical structures. The main limitation is that 3D mechanical ultrasound imaging does not overcome the physical limitations of 2D ultrasound, and that sections reconstructed from ultrasound volumes are easier to obtain but far less defined than those obtained by direct insonation. Therefore, 2D ultrasound examination still remains the gold standard for diagnosis for fetal abnormalities, but requires an experienced operator while 3D imaging can be more easily approached by less skilled operators.

## Visualization of standard views of the fetal brain starting from an axial acquisition plane

1. The acquisition plane is the transcerebellar view (Figure 14). In order to avoid shadowing from the skull base on the cerebellum and the brain stem, it is advisable to keep an angle of 45° between the midline and the ultrasound beam.

2. Rotation of both A and B planes on the z axis to align the midline with the C plane (Figure 15)

Midsagittal plane (Figure 15)

The structures can be visualized: cavum septi pellucidi (overlayed by hyperechogenic “comma-like” artifact), brain stem, pons, vermis

3. Activate the C plane, place the caliper inside the cavum septi, close to the genu of the corpus callosum, and rotate C on the z axis displaying in A the transventricular (Figure 16), transthalamic (Figure 17) and transcerebellar (Figure 18) views (corresponding to the acquisition plane)

### Axial views

Transventricular view (Figure 16)

This plane demonstrates the anterior and posterior portion of the lateral ventricles. The anterior portion of the lateral ventricles (frontal or anterior horns) appears as two comma-shaped fluid filled structures. They have a well defined lateral wall and medially are separated by the cavum septi pellucidi (CSP). With transabdominal ultrasound the CSP should always be visualized between 18 and 37 weeks. Conversely, failure to demonstrate the CSP prior to 16 weeks or later than 37 weeks is normal. In the standard transventricular plane, only the hemisphere on the far side of the transducer is usually clearly visualized, as the hemisphere close to the transducer is frequently obscured by artifacts. However, most severe cerebral lesions are bilateral or associated with a significant deviation or distortion of the midline echo, and it has been suggested that in basic examinations symmetry of the brain is assumed.

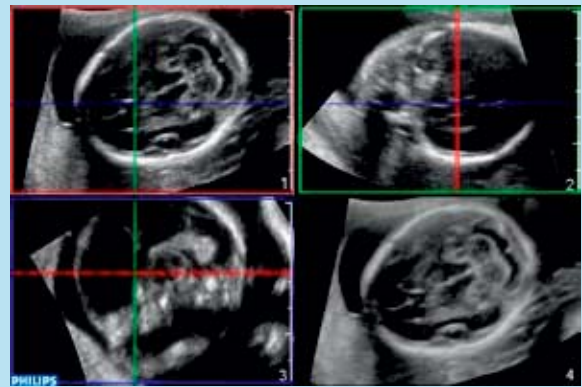


Figure 14

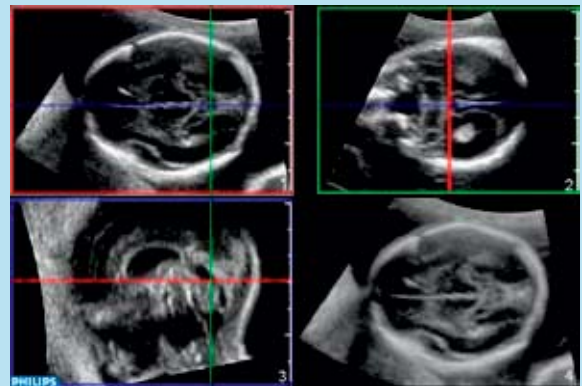


Figure 15

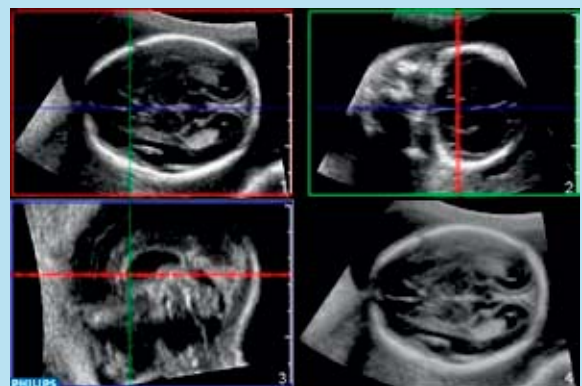


Figure 16

#### Transthalamic view (Figure 17)

Anatomic landmarks include, from anterior to posterior, the frontal horns of the lateral ventricles, the cavum septi pellucidi, the thalami and the hippocampal gyri. This plane does not add significant anatomic information to that obtained from the transventricular and transcerebellar planes, and it is mainly used for biometry of the fetal head.

#### Transcerebellar view (Figure 18)

This plane includes visualization of the frontal horns of the lateral ventricles, the CSP, thalami, cerebellum and cisterna magna.

4. The A plane shows now the transcerebellar view, and the B plane shows a coronal section of the fetal head with the orbits. Activate and rotate plane B on the z axis to orientate the midline vertically. Align the x axis with the superior aspect of the orbits and rotate it until the transfrontal coronal view is displayed in the B plane (Figure 19).

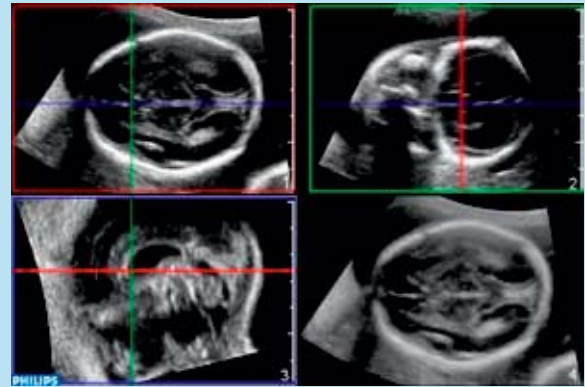


Figure 17

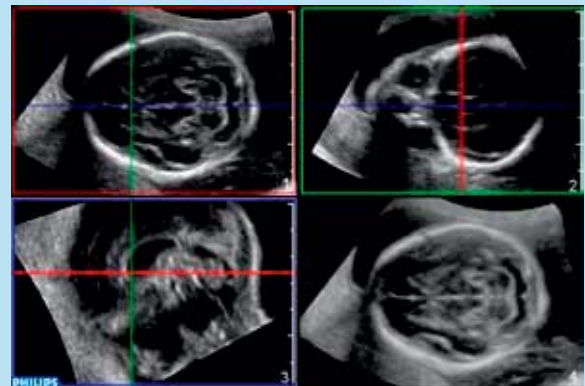


Figure 18

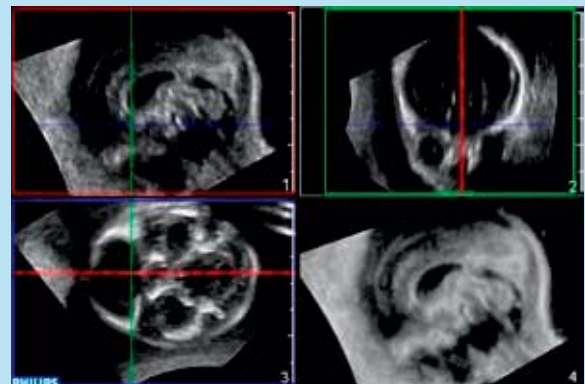


Figure 19

5. The A plane now shows a sagittal section of the fetal head. Moving the y axis in the direction of the occiput allows the visualization of the coronal sections (transfrontal, transcaudate, transthalamic, and transcerebellar) in the B plane (Figures 20, 21, 22, 23).

### Coronal views

#### Transfrontal view (Figure 20)

With 2D ultrasound the visualization of this plane is obtained through the anterior fontanelle and depicts the midline interhemispheric fissure and the anterior horns of the lateral ventricles on each side. The plane is rostral to the genu of the corpus callosum and this explains the presence of an uninterrupted interhemispheric fissure. Other structures observed are the sphenoidal bone and the ocular orbits.

#### Transcaudate view (Figure 21)

This scanning plane is at the level of the caudate nuclei. The following structures can be visualized:

The genu or anterior portion of the corpus callosum which interrupts the continuity of the interhemispheric fissure. Due to its thickness, in coronal planes the genu is observed as a more echogenic structure than the body of the corpus callosum.

The cavum septi pellucidi: depicted as an anechoic triangular structure under the corpus callosum. The lateral ventricles: found at each side surrounded by the brain cortex.

#### Transthalamic view (Figure 22)

Both thalami are found in close apposition. In some cases the third ventricle may be observed in the midline with the interventricular foramina and the atrium of the lateral ventricles and the choroid plexus slightly cranial on each side. Close to the cranial base and in the midline, the basal cistern contains the vessels of the circle of Willis and the optic chiasma.

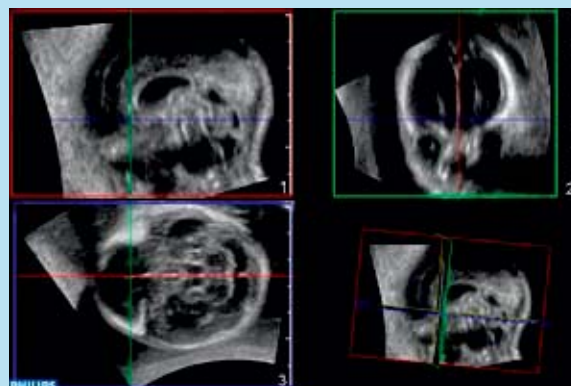


Figure 20

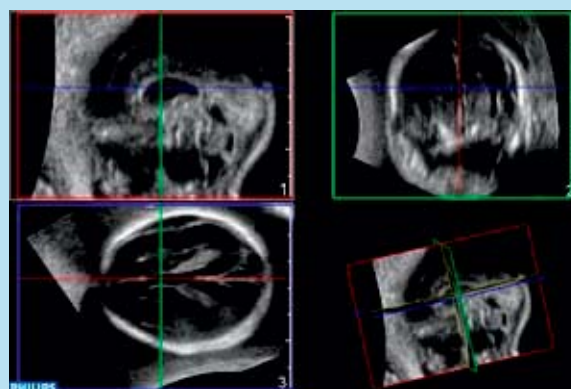


Figure 21

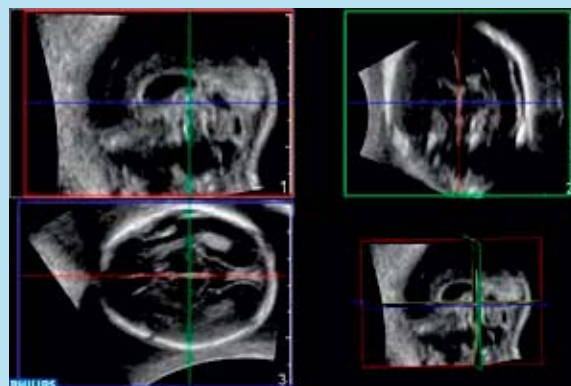


Figure 22

#### Transcerebellar view (Figure 23)

This plane is obtained through the posterior fontanelles and enables visualization of the occipital horns of the lateral ventricles and the interhemispheric fissure. Both cerebellar hemispheres and the vermis are also seen in this plane.

6. Moving the y axis towards the occiput in plane A displays a coronal view of the posterior horns of the lateral ventricle in plane B. Placement of the caliper in the distal ventricle displays an axial transventricular view in plane C (Figure 24).

7. Activate plane C and rotate on the y axis until the anterior horn of the lateral ventricle appears. Align the x axis to the frontal and occipital horns. Activate plane A then rotate on the x axis to allow the visualization of the “three horn view” (Figure 25).

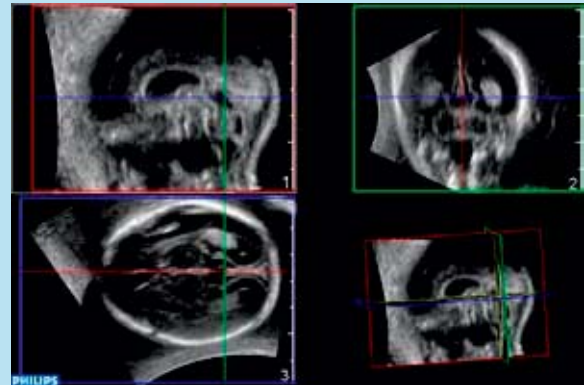


Figure 23

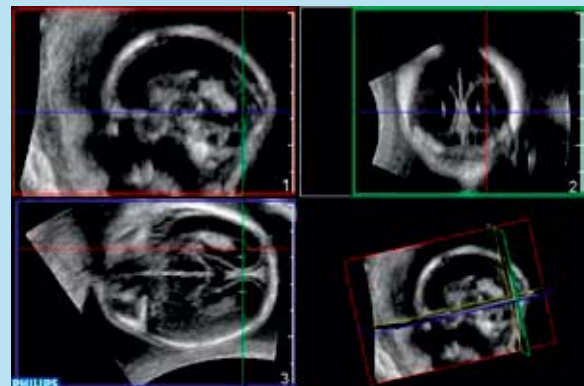


Figure 24

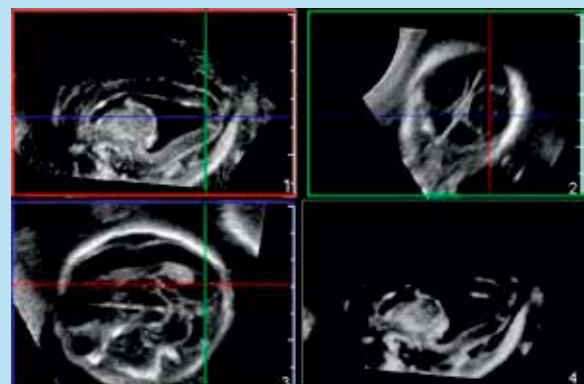


Figure 25. Parasagittal plane (three horn view)

The parasagittal plane depicts the entire lateral ventricle, the choroid plexus, the periventricular tissue and the cortex.

## References

- Correa FF, Lara C, Bellver J et al., Examination of the fetal brain by transabdominal three-dimensional ultrasound: potential for routine neurosonographic studies, *Ultrasound Obstet Gynecol.* 2006; 27: 503–508
- Merz E, Benoit B, Blaas HG et al., Standardization of three-dimensional images in obstetrics and gynecology: consensus statement, *Ultrasound Obstet Gynecol.* 2007; 29: 697–703
- Paladini D, Malinge G, Monteagudo A et al., Sonographic examination of the fetal central nervous system: guidelines for performing the ‘basic examination’ and the ‘fetal neurosonogram’, *Ultrasound Obstet Gynecol.* 2007; 29: 109–116
- Timor-Tritsch IE, Monteagudo A, Mayberry P, Three dimensional ultrasound evaluation of the fetal brain: the three horn view, *Ultrasound Obstet Gynecol.* 2006; 16: 302–306
- Pilu G, Segata M, Ghi T et al., Diagnosis of midline anomalies of the fetal brain with the three-dimensional median view, *Ultrasound Obstet Gynecol.* 2006; 27: 522–529
- Pilu G, Ghi T Carletti A et al. Three-dimensional ultrasound examination of the fetal central nervous system. *Ultrasound Obstet Gynecol.* 2007; 30: 233-245
- Vinals F, Munoz M, Naveas R, Giuliano A. Transfrontal three-dimensional visualization of midline cerebral structures. *Ultrasound Obstet Gynecol.* 2007; 30: 162-168

**Philips Medical Systems is part of  
Royal Philips Electronics**

**Interested?**

Would you like to know more about our imaginative products? Please do not hesitate to contact us.

We would be glad to hear from you.

**On the web**

[www.medical.philips.com](http://www.medical.philips.com)

**Via email**

[medical@philips.com](mailto:medical@philips.com)

**By fax**

+31 40 27 64 887

**By mail**

Philips Medical Systems  
Global Information Center  
P.O. Box 1286  
5602 BG Eindhoven  
The Netherlands

**By phone**

Asia

Tel: +852 2821 5888

Europe, Middle East, Africa

Tel: +49 7031 463 2254

Latin America

Tel: +55 11 2125 0764

North America

Tel: +425 487 7000

1 800 285 5585 (toll free, US only)



© 2007 Koninklijke Philips Electronics N.V.  
All rights are reserved.

Philips Medical Systems Nederland B.V. reserves the right to make changes in specifications and/or to discontinue any product at any time without notice or obligation and will not be liable for any consequences resulting from the use of this publication.

Printed in The Netherlands  
4522 962 28211/795 \* NOV 2007