

CT procedure with needle guidance for hepatocellular carcinoma

Philips EPIQ image fusion and navigation case study

Hepatocellular carcinoma (HCC) is a common condition worldwide. There has been increasing incidents in the United States in correlation to hepatitis C. Surgical resection, although considered a successful treatment option, is often intended for only a small population with localized disease. Minimally invasive percutaneous ablations are recognized as an effective treatment method for those who are unresectable.

Microwave ablation (MW) may be often carried out with ultrasound guidance, but has been known to be of limited use if the tumor is located near the diaphragm. In such cases, CT guidance has been able to overcome this limitation and successfully assist in accessing the lesion for treatment. One drawback however, is the increased radiation exposure to patients during the procedure because multiple scans are often acquired to confirm proper MW probe placement.

The Philips image fusion and navigation system demonstrates its clinical utility for a technically challenging case by displaying the needle trajectory in real time, to facilitate an effective approach for MW probe placement.

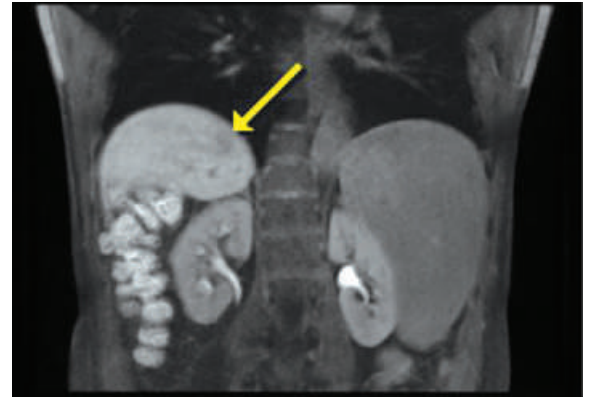
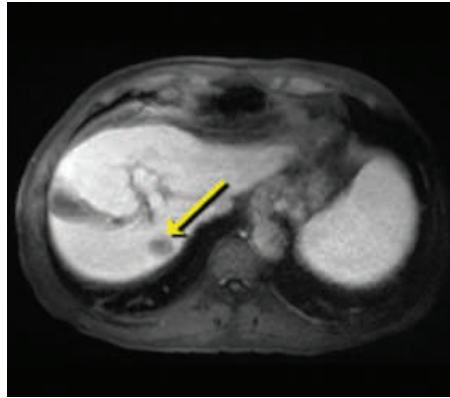


PHILIPS

One complex case – simplified

Patient history

A 57-year-old male with a history of hepatitis C, presented with a 2.1 cm lesion in Segment 7 adjacent to the hepatic dome.



2.1 cm lesion in Segment 7 adjacent to the hepatic dome

This progressive mass demonstrated well on contrast enhanced MRI, in the arterial and portal venous washout phase, consistent with hepatocellular carcinoma.

This patient was not eligible for surgical resection, therefore, the plan of care was combined chemo-embolization and percutaneous microwave ablation.

Total bilirubin: 1.0

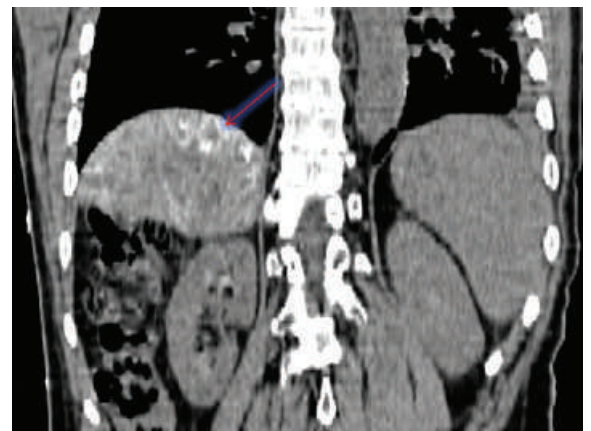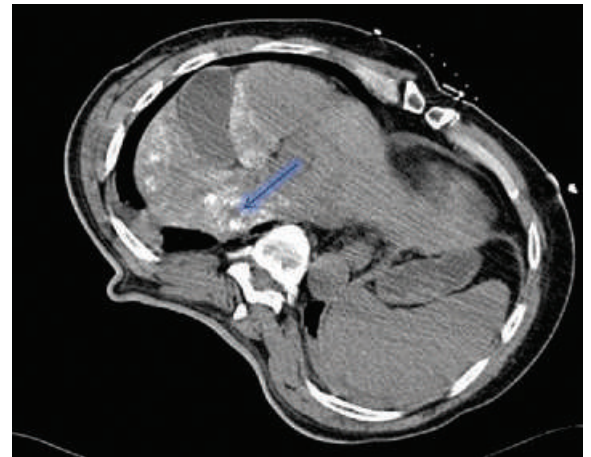
INR: 1.3

Platelets: 23

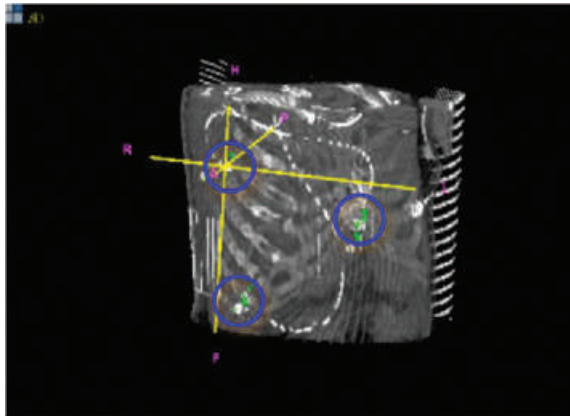
AFP: 2,100

Lesion location in combination with an anatomical variant imposed a great technical challenge to this procedure.

A severely atrophic Segment 4 provided a great challenge due to the presence of small bowel occupying the space laterally. This lesion was further enclosed posteriorly with lung and major vessels.



Pre-procedure planning CT



Spatial mapping to correlate image space to patient space

In addition, this patient expressed great concern about damage to surrounding tissue. With all of these factors in mind, very strong emphasis was made on precise needle placement to obviate any complications such as bleeding, pneumothorax, etc.), as well as to achieve a complete response to treatment.

A pre-procedure non-enhanced CT scan was acquired axially, with the patient positioned supine. The Philips patient trackers were placed on the skin surface, near the area of interest to be used as registration fiducials.

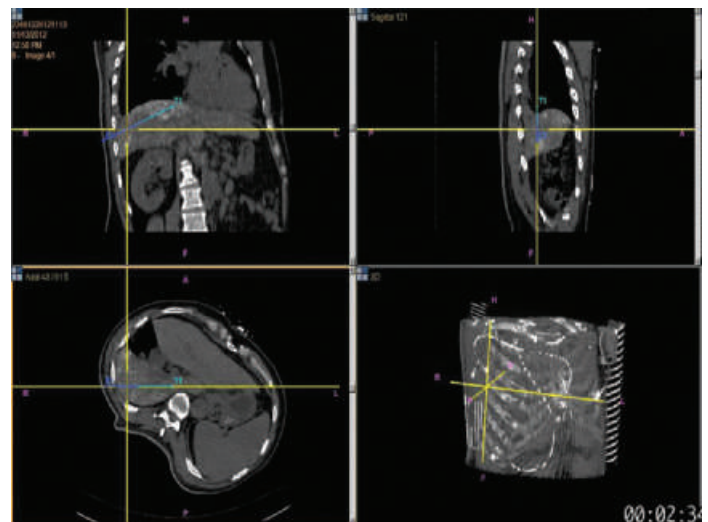
The target location was predefined on the axial series.

In addition, an entry point was pre-defined to ensure the projected needle path would avoid critical areas including lung and bowel.

This planned trajectory will later assist in placing the microwave probe (17 G/20 cm) in a target at a very sensitive location.

The Philips automatic registration feature is used to promptly align the patient's physical space to the patient's image space, using the position sensors embedded in the registration fiducials. Registration accuracy is optimized by suspending respiration to keep consistent with the respiratory state during scan acquisition.

The characteristic benefit of real-time imaging with ultrasound in this case is shadowed by a limited scanning window. Neighboring lung and bowel necessitates greater dependence on CT.

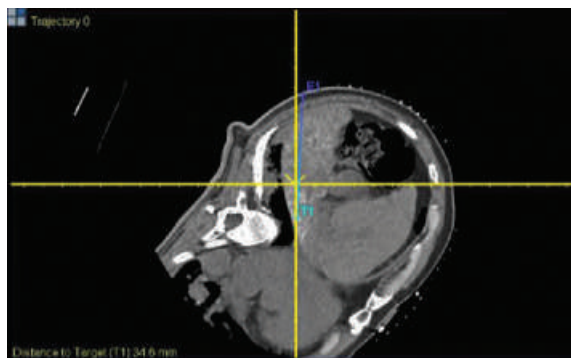


Target defined in planning

For lesion access, the Philips adaptive needle tracker is used for needle tracking. This device includes an embedded sensor coil, and is affixed to the microwave probe along the shaft approximately 14 cm from the tip. Once the tip offset is entered into the software, Philips image fusion and navigation technology extrapolates the location of the needle tip to display it in real time. The location of the needle tip is represented as a yellow cross-hair.



Philips adaptive needle tracker



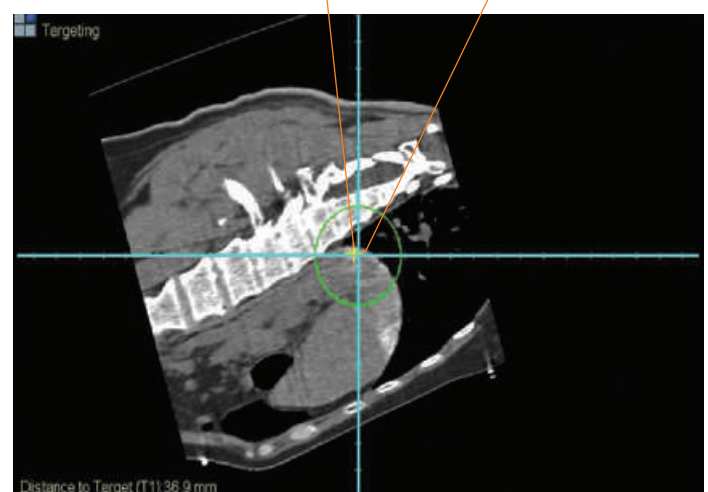
The oblique views are made available during the navigation phase to ensure vital structures are avoided. The trajectory 0/90 views reformat the pre-procedural CT along the axis of the needle to provide visualization of the projected needle path.

Philips image fusion and navigation also displays the targeting view for assistance in adhering to the planned trajectory. Consider the target view as looking at the target through the barrel of the needle. The tip of the needle is aimed to superimpose on the target.

The MW probe is positioned posterolaterally, and aligned to intersect the lesion, and ultimately accessed in a single pass despite the narrow window of access. The physician relied heavily on the targeting view and advanced the needle incrementally. Needle placement was done in apnea with patient under general anesthesia, again to optimize registration accuracy.

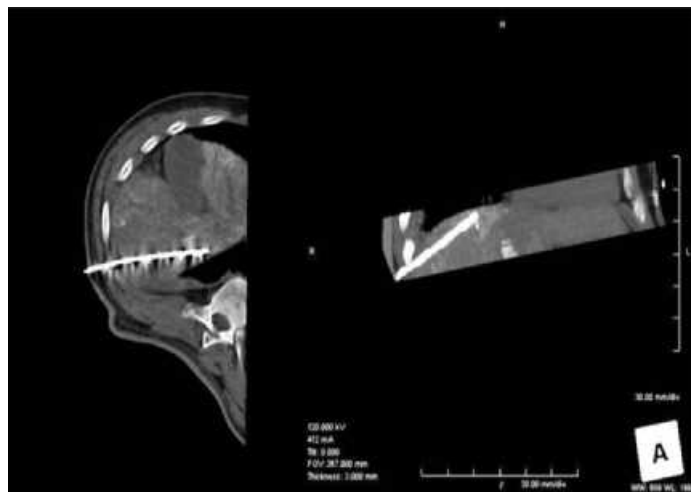
The needle tip – yellow crosshair

The target point – blue crosshair

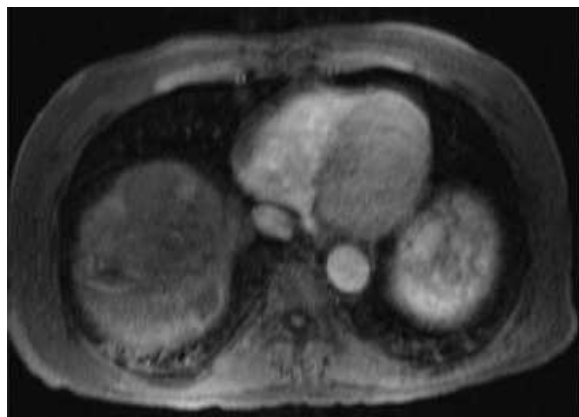


Targeting view

A confirmation CT scan subsequently confirmed the tip of the interventional device to be at the target, within 3 mm of the diaphragm. Ablative therapy ensured complete response, with no complications.



Reconstructed views in plan with MW probe



One month post treatment

On a follow-up visit, at one month post treatment, MRI demonstrates 100% necrosis of the tumor without damage to surrounding vessels or structures. Complete response as per modified RECIST criteria.

Please visit www.philips.com/percunav



© 2014 Koninklijke Philips N.V.
All rights are reserved.

Philips Healthcare reserves the right to make changes in specifications and/or to discontinue any product at any time without notice or obligation and will not be liable for any consequences resulting from the use of this publication.

Philips Healthcare is part of Royal Philips

www.philips.com/healthcare
healthcare@philips.com

Printed in The Netherlands
4522 962 99251 * JAN 2014