FieldStrength

Publication for the
Philips MRI Community

ISSUE 47 – 2012/3

Bonn proves the power of Ingenia 3.0T in prostate imaging

Dr. Willinek sees excellent image quality and patient handling for prostate imaging.

This article is part of FieldStrength issue 47
2012/3

"Ingenia allows us to perform a prostate exam and a pelvis exam without coil change or repositioning the patient."

Dr. Winfried A. Willinek is Professor of Radiology and Vice-Chair of the Department of Radiology at the University of Bonn, Germany. He received board certification from the German Board of Radiology in 2005. Within the Department of Radiology he holds a range of additional posts including Director of MR Imaging and Assistant Director of Medical Education.

Bonn proves the power of Ingenia 3.0T in prostate imaging

Excellent image quality and patient handling provide the best of all worlds for prostate imaging

Winfried A. Willinek, MD, Professor of Radiology at the University of Bonn (Germany), was one of the first radiologists in the world to evaluate Philips' groundbreaking MultiTransmit technology in 2008. Impressed as he was with that development, his recent experiences with the Philips Ingenia 3.0T have convinced him that this system provides an even greater change in MRI. According to Dr. Willinek, two of the major beneficiaries of this system are prostate imaging and MRI-guided prostate biopsies.

Major requirements of prostate MRI are high spatial resolution and high signal-to-noise ratio (SNR) to be able to accurately visualize the fine anatomy of the prostate. In order to get high SNR at 1.5T an endorectal coil was inserted into the rectum close to the prostate. However, a disadvantage of endorectal coils is the limited field of view (FOV). The need for such coils has also been one of the main reasons for the limited patient acceptance of prostate MRI at 1.5T. Artifacts introduced by patient movement over the duration of the exam, as well as by the endorectal coil were also recognized problems, especially at 1.5T.

"The whole concept behind the Ingenia 3.0T makes it comfortable to work with," says Dr. Willinek. "The system's digital architecture provides high SNR that can be translated into higher spatial resolution. In combination with Ingenia's excellent homogeneity this allows us to visualize prostate anatomy without the need to use an endorectal coil. In Bonn we simply use the dS Torso coil solution that consists of the integrated posterior coil and a lightweight, large coverage anterior coil – this is an easy approach for both patients and MR team."

Easy adaptation of FOV for staging

Besides the small FOV needed for imaging the prostate itself, a comprehensive prostate imaging protocol must also include sequences with extended FOV to examine the entire pelvic region. "And here's the real beauty of the Ingenia 3.0T. With the system's advanced and user-friendly coil handling, the technologist can easily extend the FOV for performing staging of the pelvic region. The system will automatically select the coil elements for the larger FOV, and the patient and coils don't need to be repositioned," says Dr. Willinek.

CONTINUE

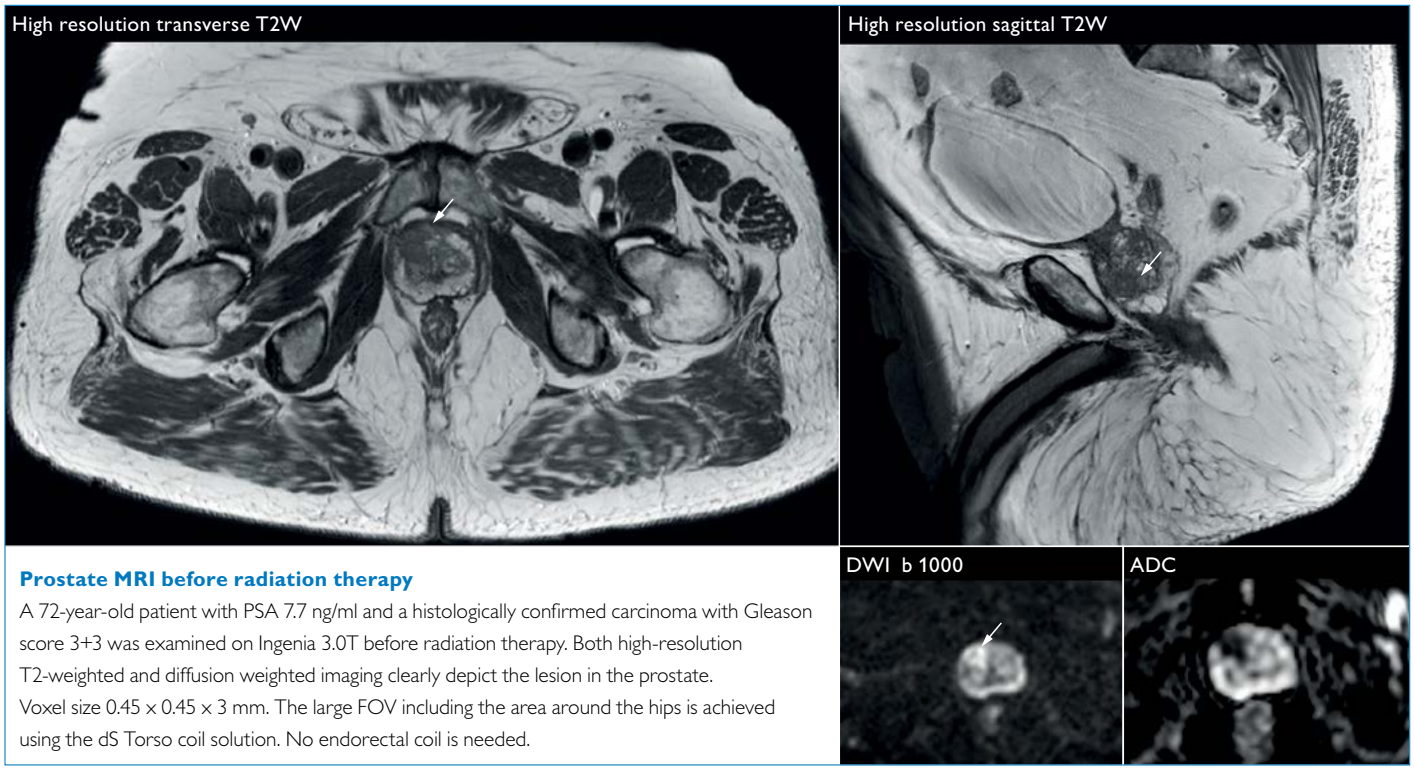

Prostate MRI before radiation therapy
A 72-year-old patient with PSA 7.7 ng/ml and a histologically confirmed carcinoma with Gleason score 3+3 was examined on Ingenia 3.0T before radiation therapy. Both high-resolution T2-weighted and diffusion weighted imaging clearly depict the lesion in the prostate. Voxel size 0.45 x 0.45 x 3 mm. The large FOV including the area around the hips is achieved using the dS Torso coil solution. No endorectal coil is needed.

"Patients are put at ease and can lie comfortably in the system, which I believe is the most important criterion for successful MRI exams."

Multi-parametric imaging for confident diagnosis

Dr. Willinek regards multi-parametric imaging a reliable method to help detect lesions in patients who have had suspicious findings on PSA tests. This technique becomes even more powerful with the high SNR of the Ingenia 3.0T.

"We have developed a specific series of sequences for lesion visualization with good sensitivity and specificity," says Dr. Willinek. "To study morphology, we start with T2-weighted imaging at very high resolution. We then proceed with functional assessment. With diffusion weighted imaging (DWI) on Ingenia 3.0T, we are now able to achieve convincingly better imaging quality than formerly with multiple b-values allowing us to get really exquisite, homogeneous DWI images. We continue with a 3D eTHRIVE dynamic acquisition at high temporal resolution. And we complete the exam with MR spectroscopy, which is valuable for providing molecular information in the prostate." Development of protocols and clinical applications is performed in a close collaboration between the Department of Radiology and Philips Senior Clinical Scientist Jürgen Gieseke.

"In every patient we perform these four acquisition techniques: DWI, 3D eTHRIVE, and T2-weighted sagittal and transverse images with high spatial resolution, and additional T2-weighted sequences covering the hips. This means that examination time is around 45 minutes. For diagnosis, the gain of using the four techniques is tremendous, but of course, the patient has to stay comfortable over this time. The system's wide bore can help to put patients at ease and to lie comfortably in the system, which I believe is one of the most important criteria for successful MRI exams. And, it makes patient handling much easier for the technologist."

"In some cases, only one or two sequences of the multiparametric exam show suspicious lesions. Therefore we use a scoring method to standardize reporting."

High image quality helps MR-guided biopsies

As biopsies are often stressful for patients, all MR-guided biopsies at Bonn are now performed on the wide bore Ingenia 3.0T system. "A biopsy will take upward of 40 minutes," says Dr. Willinek. "If a patient is not comfortable, he will move and all stereotactic data is lost. Not only does the wide bore help to put patients at ease, but it also improves the workflow because we don't have to take the patient out of the system to reposition the guide. Another big plus of the Ingenia 3.0T is that it gives the same image quality standard for biopsy guidance as for diagnostic imaging despite the different positioning of the patient."

"A big plus of Ingenia 3.0T is that it gives the same image quality standard for biopsy guidance as for diagnostic imaging."

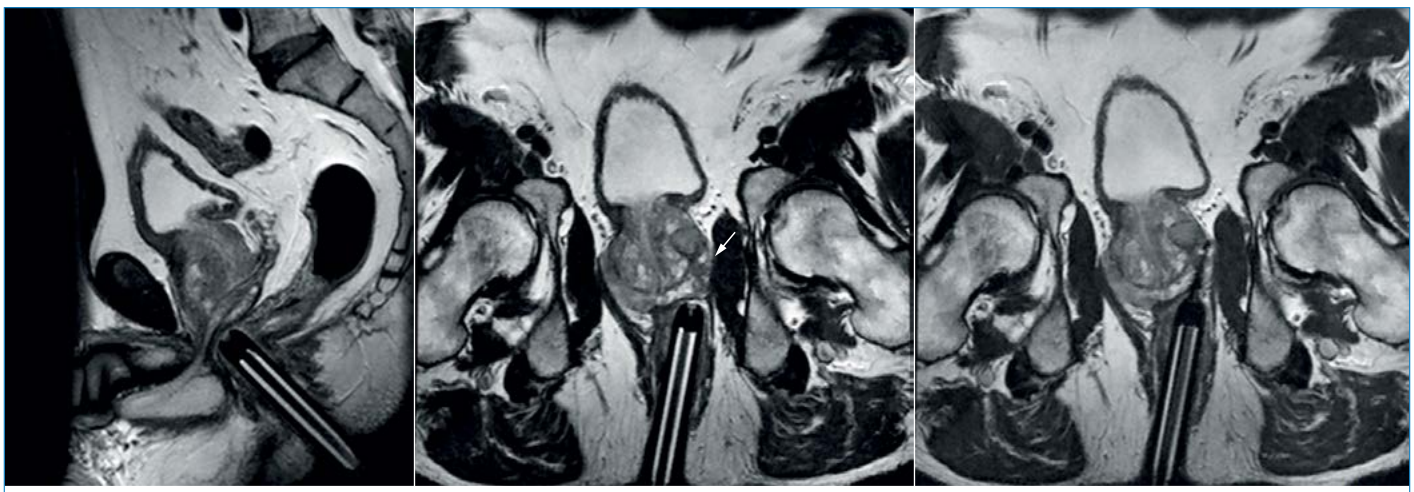

MR-guided prostate biopsy
A 75 -year-old patient with increasing PSA elevation and two suspicious lesions in the rim underwent prostate biopsy under MR image guidance. Note the high image quality. The sagittal slice is parallel to the biopsy direction. Voxel size 0.65 x 0.65 x 2 mm.

Dr. Willinek predicts a big future for MR-guided biopsies. "We have seen patients with positive findings after MR-guided biopsy who may have previously undergone up to three negative US-guided biopsies including sextant biopsies, twelve core biopsies and even saturation biopsies of 20 to 40 cores. In these cases subsequent MR-guided biopsies were performed with typically only one to three cores and histopathology confirmed positive findings."

"Fewer core biopsies are not only preferred by the patients but also from a medical standpoint since each puncture through the rectum wall carries the risk of infection. This is of particular interest in times of increasing numbers of multi-resistant bacteria."

Dr. Willinek does not recommend, however, that every patient with an elevated PSA should receive an MR-guided biopsy. "We don't have the scanning capacity for that at present. I believe we should currently limit the patient cohort to men who have had one or more negative US-guided biopsies. We then already have a significant number of patients who can really benefit from this approach."

"The high SNR and excellent homogeneity of Ingenia 3.0T allow us to visualize prostate anatomy without the need to use an endorectal coil."