

# FieldStrength

Publication for the Philips MRI Community

Issue 41 – September 2010



## MR-OR suite enables intraoperative brain MRI

The Montreal Children's Hospital uses MRI to check completeness of tumor resection during surgery



This article is part of  
Field Strength issue 41,  
September 2010

**PHILIPS**  
sense and simplicity

# MR-OR suite enables intra-operative brain MRI

The Montreal Children's Hospital uses MRI to check completeness of tumor resection during surgery




Jean-Pierre Farmer, MD

During brain tumor resection it is often difficult to see whether the entire tumor has been removed. Therefore, the [neurosurgical MR-OR Suite at The Montreal Children's Hospital](#) includes an Achieva 3.0T scanner prepared for intraoperative MR imaging. Montreal physicians have performed surgery with MR guidance on more than 30 patients, mainly tumor or epilepsy cases, since its installation in late 2009.

“Whether it’s for epilepsy or brain tumors, the extent of resection is very important to the patient’s outcome,” says Jean-Pierre Farmer, MD, Neurosurgeon and Surgeon-in-Chief at The Montreal Children’s Hospital of The McGill University Health Centre, and Head of the Department of Pediatric Surgery at McGill University Health Centre. “Without imaging during surgery it can be necessary to stop resecting before the whole tumor is removed to reduce the chance of damaging vital areas. We wanted to be able to perform MR imaging during neurosurgery to better assess the extent of resection in children during neurosurgery.”

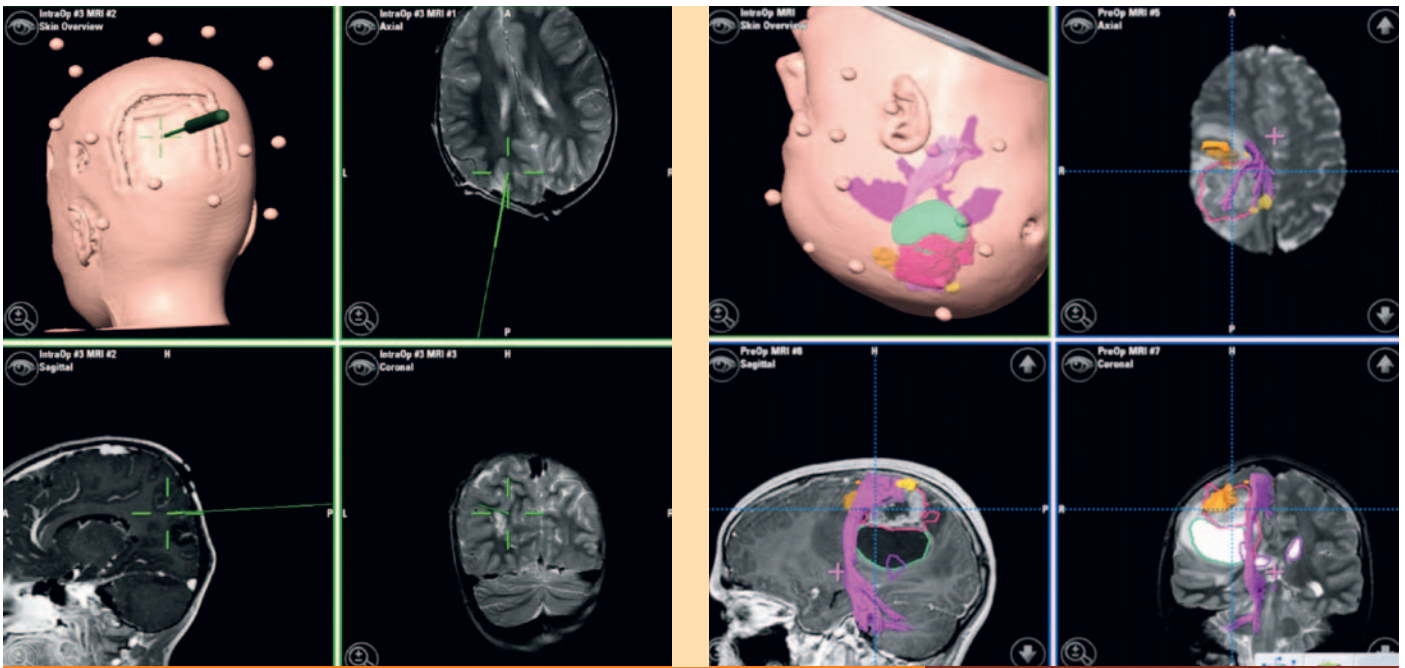
This two-fold advantage – extensive resection and preserving function – is the biggest advantage of the suite, says Dr. Farmer. “There are cases where it’s crucial that the resection will be as complete as possible. It can spare a child from having to face a second surgery.”

“Whether it’s for epilepsy or brain tumors, the extent of resection is very important to the patient’s outcome.”

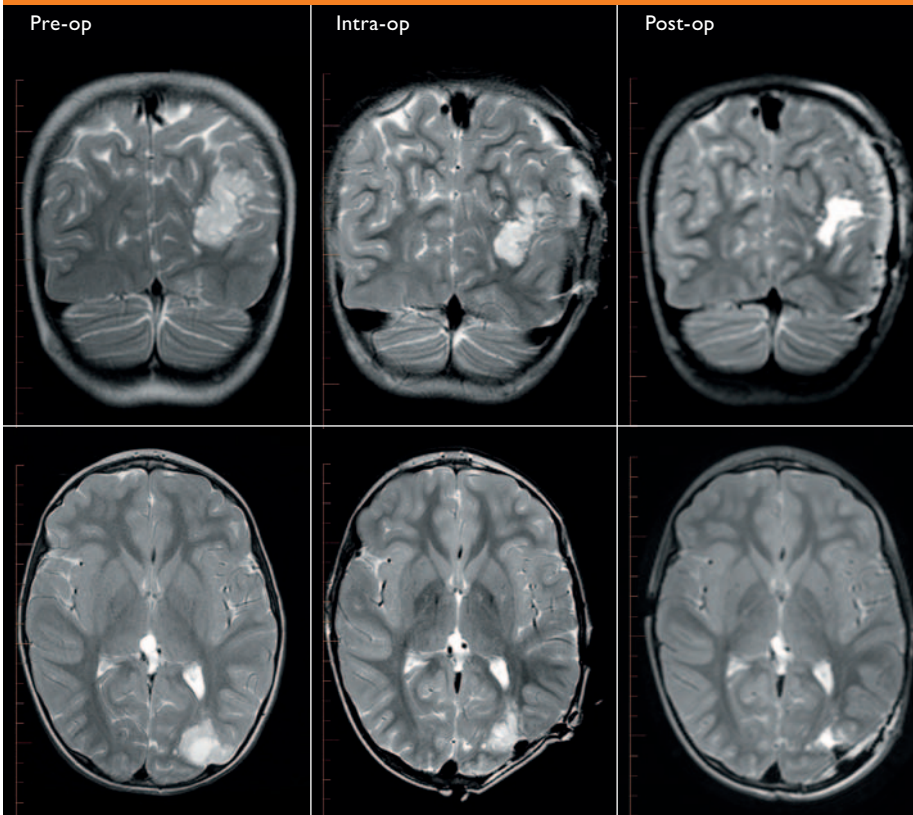


Floor plan of the MR-OR suite

“For Emilie, the intraoperative MRI had a very big impact.”



MR guidance during neurosurgery



Images of a patient with dysembryoplastic neuroepithelial tumor (DNET) and seizures. Note unsuspected deep residual disease on the intraoperative scan and contrast with the post-op scan showing complete resection. On top: MR views used for surgical navigation during neurosurgery procedures.



Impression of the MR-OR suite's two-room concept with the Achieva 3.0T on the left

“With ultrasound, it looked like a complete resection, but MR still showed deeper roots of the tumor that seemed safe to remove.”

#### Advanced equipment enables advanced surgeries

The hospital chose a two-room solution, so the MR system is also accessible to patients for diagnostic imaging. In this way, the Achieva 3.0T also helps reduce MRI waiting lists.

In addition to the Achieva 3.0T MRI in the scanner room, the OR has a surgical microscope that accepts the BrainLab navigational program. MR images are transposed onto the program, enabling the accurate navigation within the brain during surgery. If a patient underwent an fMRI or tractography study, those images can also be overlaid on the navigational scan.

“We’re coupling a navigational scan with the full detailed study we did previously for seeing best detail,” says Dr. Farmer. “This helps us to extensively resect in specific areas, and also preserve adjacent eloquent areas for the patient’s quality of life.”

For intraoperative MRI a special coil is used, which has two separate halves and is sterilizable for surgical use.

#### First patient a success story

The child who cut the ribbon at the opening of the MR-OR suite was [Dr. Farmer’s first patient, Emilie](#). “She had a low-grade tumor that was causing epilepsy. Because it was low grade and very close to the structure of the brain, it looked very similar to grey matter of the brain during surgery. With ultrasound, it looked like I had a complete resection, but then I took her for an MR scan. To my surprise there were still deeper roots of the tumor and, based on the fiber tracking that we had done previously, they seemed to be safe to remove.”

Dr. Farmer brought her back to the OR. “Because they had only provisionally closed the membrane and the skin, it took no time to re-drape and get to the tumor. “We knew exactly where the residual fragment was. We removed the residual fragment and did another MRI to be sure we had removed all we wanted to. So she probably has no residual tumor at all, and her chance of having been cured of the epilepsy is over 90 percent. Time will tell, but it looks very good. For Emilie, the intraoperative MRI had a very big impact.”

#### Beyond pediatrics

Cases such as Emilie’s could become more common in the near future, also for adults. “This setup can be used for all types of neurosurgery,” says Dr. Farmer. “We are looking at other applications as well, particularly skull-base surgery and orthopedic applications. In these cases it’s very important that the resection is complete.”